


Why I'm here:

COLD-STUNNING

Patient : **TINKERBELL**
Species : **KEMP'S RIDLEY**
Latin: **LEPIDOCHELYS kempii**
Age : **JUVENILE**
Gender : **UNKNOWN**
Weight : **3 LBS**
Found : **ROCK HARBOR, MASS**
Arrived : **DECEMBER 18, 2007**
Rescued by : **NEW ENGLAND**
AQUARIUM



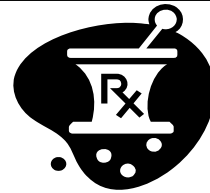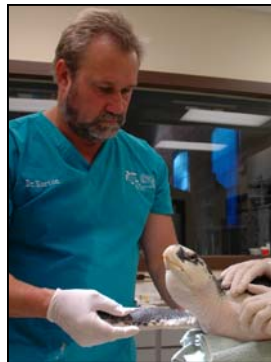Exam Findings:

STABLE CONDITION FROM
TREATMENT AT NEAQ

Secondary Findings:

OSTEOMYELITIS
(A BONE INFECTION
ALONG THE
MARGINAL SCUTES)

OSTEOMYELITIS
IN SHOULDER



**INITIAL
TREATMENT
FOR: TINKER-
BELL**

CEFTAZIDIME : ANTIBIOTIC

FLUCONAZOLE : ANTI-FUNGAL

DOXIROBE : TOPICAL
OSTEOMYELITIS TREATMENT

BAYTRIL : ORAL OSTEOMYELITIS
TREATMENT

PHYSICAL THERAPY : IMPROVES
FRONT FLIPPER MOBILITY

How YOU can help me:

READ MORE ABOUT ME!
DONATE TO HELP SUPPORT
OSTEOMYELITIS PATIENTS!

Current Weight:

888 lbs

